

## Preliminary results of comparison NBS with direct cortical stimulation in clinical setting, including case report

MD PhD Thomas Picht\*, MD PhD Olaf Süß\*, Prof. MD PhD Stephan A. Brandt\*\*, MD PhD Sein Schmidt\*\*

\* Dept of Neurosurgery, Charité Universitätsmedizin, Berlin \*\* Dept of Neurology, Charité Universitätsmedizin, Berlin

### Background

A scientific comparative study of the Nexstim Navigated Brain Stimulation (NBS) System with direct cortical stimulation (DCS) is being conducted. Invasive DCS is widely held as the gold standard in motor mapping. Objectives of the study are to:

- Evaluate the concordance of NBS and DCS results
- Evaluate the potential to use NBS routinely in clinical practice
- Determine whether NBS results could impact surgical strategy


This paper reports on the preliminary findings from the initial cohort of 14 patients.

### Study group

In the initial phase of the study, 14 patients with malignant tumors of the central region scheduled for elective surgery were recruited. Inclusion criteria were tumors of the central region with obscured functional anatomy and/or motor impairment due to the mass effect or the infiltrating growth pattern of the lesion.

### Methods

The enrolled patients had whole-head MR-images taken and neurological status confirmed within 72 hours prior to surgery. The preliminary surgical approach was determined. Prior to surgery, patients underwent non-invasive mapping of the primary motor cortex with the Nexstim NBS System (Nexstim Oy, Finland). The NBS mapping was performed by a trained medical doctor. After the motor threshold was determined for the individual patient on the side of



the lesion, mapping was systematically performed with the aid of the NBS software grid displayed on the NBS System screen. Following analysis of the NBS results, the preliminary surgical approach was re-assessed by the neurosurgical team.

During surgery, craniotomy was performed to expose the central region. The central sulcus was localized with somatosensory evoked potential phase reversal (SSEP). Peritumoral area of the cortex was mapped with monopolar direct cortical stimulation in a 5-10 mm pattern.

Neurological status of the patients was assessed post-operatively.

## Results

NBS motor mapping was successful in 100% of patients, mapping time was 45–90 min. The Nexstim NBS System provided a detailed map of the peritumoral somatotopy preoperatively in all 14 patients. There were no adverse events during NBS mapping. Mapping with DCS was successful in 11 cases. In two cases DCS was not feasible, since a biopsy via minimal invasive approach was performed. In one case DCS mapping was aborted because of severe intraoperative bleeding. Mean DCS mapping time was 30 min, due to the restricted stimulation area.

Results of both methods were co-registered and compared. Overall, there was good correspondence between the peritumoral somatotopy mapped by the Nexstim NBS and that achieved with direct electrocortical stimulation.

The surgical strategy was modified due to the Nexstim NBS results in five out of fourteen patients (36%). In all cases the tumor was successfully resected with no permanent worsening of motor function post-operatively.

## Conclusion

Preliminary results indicate good agreement between NBS and DCS mapping data. Additionally, NBS mapping was feasible in all fourteen cases, whereas direct cortical mapping could be performed in eleven out of fourteen cases. NBS mapping was well tolerated by all patients.

NBS data are useful in confirming the surgical approach and have the potential to improve surgical planning, prior to craniotomy.

The time and effort involved in establishing the Nexstim NBS System as part of the clinical workflow has shown good initial outcomes. As part of the clinical practice, the system was ready to map in (5–10 min). Minimal training and time has been required to teach operators how to use the NBS System reliably for motor mapping.

In order to evaluate the accuracy of Nexstim NBS in comparison with direct electrocortical mapping in a statistically profound manner, a total of 35 patients are planned to be examined under our study protocol. The results of the completed study are to be submitted for publication in a neurosurgical journal.

## Case report

Patient presented with tumor (lung CA metastasis) and slight left-sided hemiparesis, Figure 1. In order to decide whether the tumor could be resected or treated with radiation therapy, information was needed on the location of the functional areas in proportion to the tumor.

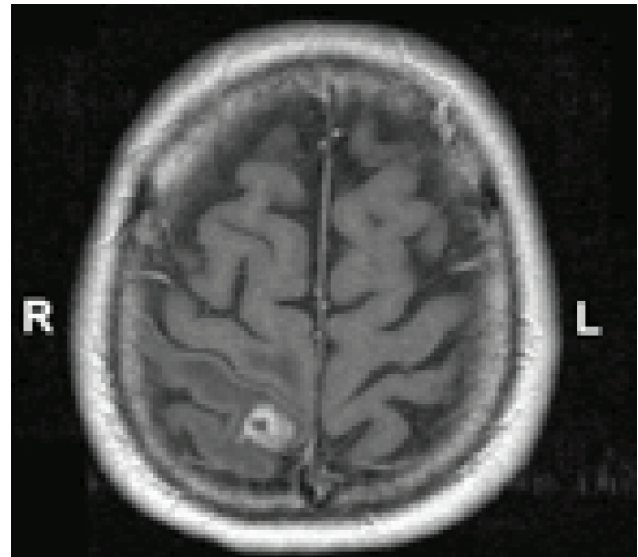


Figure 1. MRI slice view, tumor (lung CA metastasis)

Non-invasive motor mapping was performed pre-operatively with the Nexstim NBS System. Motor threshold was found for the patient and mapping performed. Co-registration of the head and the MR-image of the brain permitted visualization of the location of stimulation pulses by stereotactic navigation. The NBS system operator was able to view the electric field distribution caused by the magnetic pulse, modeled according to the head structure, on the system computer screen, Figure 2. To systematically map the motor areas, the operator followed a grid pattern displayed on the system screen to guide placing of the TMS coil.

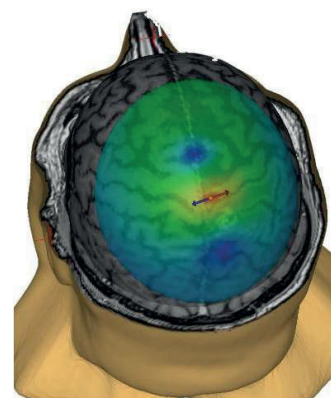


Figure 2. E-field intensity, distribution and direction as displayed in NBS screen.

Motor evoked potentials (MEP) due to the TMS pulses were recorded with EMG. The cortical areas representing the foot muscle (TA) and the hand muscles (APB, ADM) were successfully located. Figure 3A shows the NBS System display of stimuli given (orange markers denote cortical areas eliciting maximum EMG responses, white markers all other locations). On the right hand side, Figure 3B shows the NBS System display of the primary "hot spots" with orange markers.

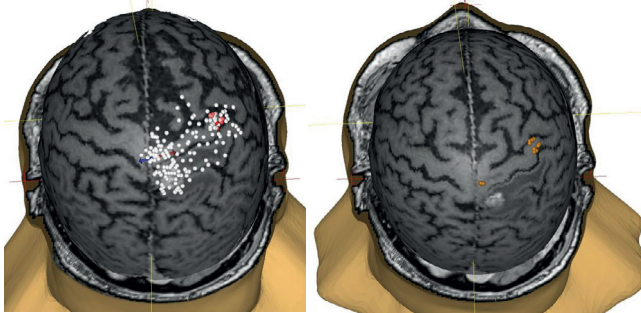


Figure 3A. NBS display all stimulated locations (white marker = Stimulating E-field maximum location) Figure 3B. NBS display locations eliciting EMG responses, orange markers (APB, ADM, TA)

The neurosurgical team determined that the tumor was operable and made the preliminary surgical strategy based on the NBS mapping results. Prior to resection of the tumor the NBS mapping results were confirmed with the direct cortical stimulation. A 5 cm x 4 cm craniotomy was performed and electrodes were placed over the cortex in a 5-10 mm grid pattern. Areas representing the foot (TA) and the hand (APB, ADM) were successfully located and marked. A comparison of the results as displayed on the respective screens is shown in Figure 4. The results of the two systems were considered to be in good agreement and the tumor was resected according to the surgical approach originally guided by the preoperative NBS mapping data. A detailed view of the comparison between the NBS data and the DCS data is shown in Figure 5.

### Acknowledgements

All figures and photographs courtesy of Charité Universitätsmedizin, Berlin

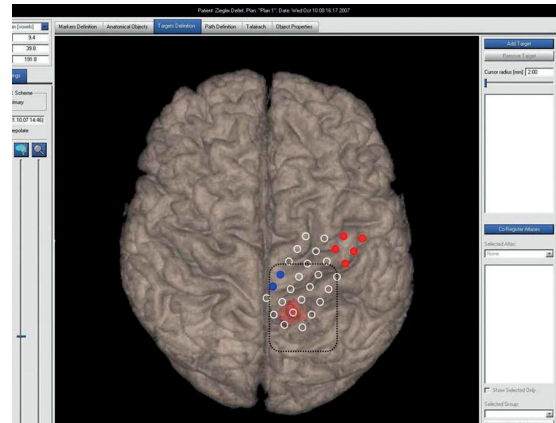
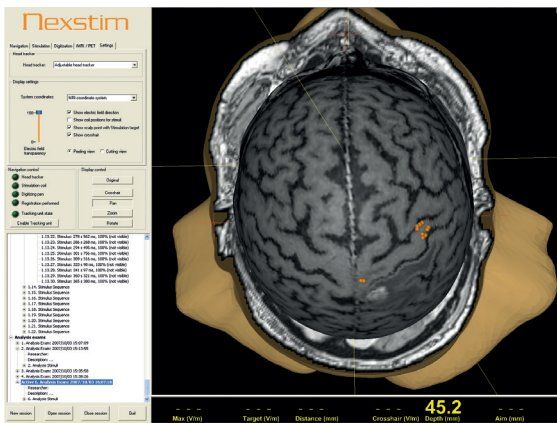


Figure 4. Comparison of NBS (left) and DCS (right) results

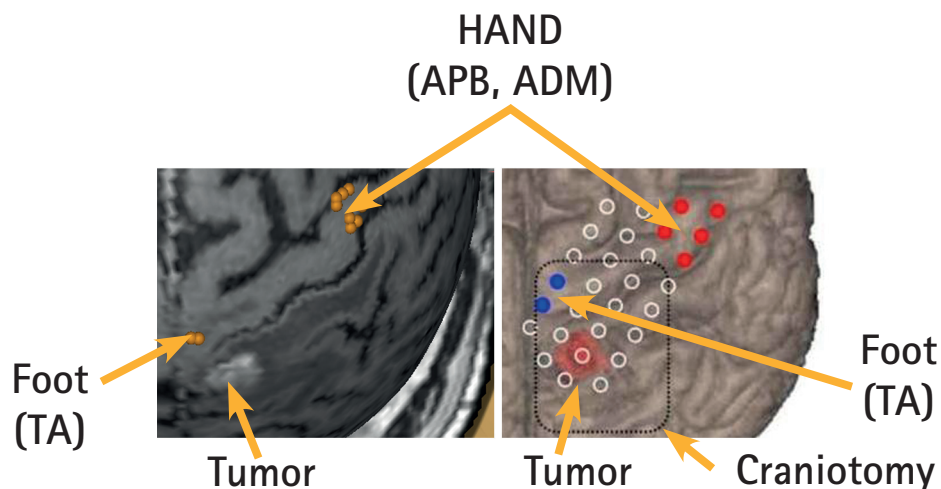


Figure 5. Detailed comparison of NBS (left) and DCS (right) results